

Original article:

Communication between musculocutaneous nerve and median nerve – types and incidence in Eastern Indian Population

¹Dr.Soumali Biswas , ² Dr.Anwesa Pal, ³ Dr.Asis Kumar Ghoshal

¹Demonstrator ,Department of Anatomy, Institute of Post –Graduate Medical Education and Research, Kolkata-20.

²Demonstrator, Department of Anatomy, Institute of Post–Graduate Medical Education and Research, Kolkata-20.

³Professor and Head of the department, Department of Anatomy, Institute of Post –Graduate Medical Education and Research,Kolkata-20.

Corresponding Author: Dr.Anwesa Pal

ABSTRACT

INTRODUCTION: Musculocutaneous nerve and median nerve, both branches from median nerve, may present with a number of variations. The most commonly noted variation is the presence of a communicating branch between the two nerves which may arise at different levels in respect to coracobrachialis muscle.

METHODS: The dissection was carried out in 50 upper limbs of formalin hardened human cadavers of both the sexes in the Department of Anatomy, IPGME&R, Kolkata, West Bengal. All the measurements were taken thrice with graduated metric scale and the mean value of such observations was taken into account.

OBSERVATIONS AND RESULTS: In 22% cases a communicating branch was found between the musculocutaneous nerve and median nerve. In 4% cases, there was complete fusion between the two nerves. In the remaining 74% cases, both the nerves followed their normal course and no communication was present. The mean length of the communicating branch was seen to be 6.5cm.

CONCLUSION: The abnormal communication between the two nerves is very important as injury to musculocutaneous nerve or its communicating branch may lead to unexplained signs and symptoms of median nerve neuropathy as fibres of the two nerves are connected with each other. Also, the different types of anomalous communication are important for surgeons and anesthetists as the musculocutaneous nerve may be injured during arthroscopies, coracoid process grafting or shoulder surgeries.

KEY WORDS: Musculocutaneous nerves, Median nerve, communicating branch.

INTRODUCTION

Musculocutaneous nerve is one of the branches of brachial plexus (conveying fibres of C5, C6 & C7) and supplies most of the muscles of the anterior compartment of arm and gives cutaneous supply to the antero-lateral side of forearm up to base of the thenar eminence through lateral cutaneous nerve of forearm. It also gives articular twig to the elbow joint and nutrient artery to the humerus¹

Median nerve is formed by joining lateral and medial root from lateral and medial cord of brachial

plexus respectively (conveying fibres of C5, C6, C7 and C8, T1 respectively). It supplies most of the flexor group of muscles of the forearm, gives articular twig to the elbow joint, all the three radio-ulnar joints and wrist joint, sensory supply to the skin over thenar eminence and central region of palm through palmar cutaneous branch¹

Variation in communication and their incidence between musculocutaneous nerve and median nerve have become the area of interest for anatomists, radiologists and orthopaedic surgeons

for several years as there may be some unusual clinical symptoms due to variation in their branching pattern.² Venieratos and Anagnostopoulou in 1998 described that the most common variation of these nerves is the communication between them,³ though others have described the absence of musculocutaneous nerve as the most common variation, where muscles of anterior compartment of arm are supplied by the branches from median nerve.^{4,5,6,7,8} Different studies have been reported about it from different parts of India.^{9,10,11}

AIMS AND OBJECTIVES

Aim of our study is to enlighten different types of communication between the two nerves with exact topography and its incidence in the population of Eastern India.

MATERIAL AND METHODS

This study was conducted over 25 cadavers (50 upper limbs) in the Department of Anatomy, IPGME&R, Kolkata. Dissection was done by us according to the method described in Cunningham's manual with the help of dissecting box. Roots, trunks, divisions, cords and branches of brachial plexus were dissected and measurements were taken with graduated metric scale. All the measurements were taken thrice and the mean value of each was taken to avoid observational bias.

OBSERVATIONS AND RESULTS

Out of 50 upper limbs dissected we found communication between musculocutaneous nerve and median nerve in 11 limbs(22%) and in 2 limbs (4%) there were complete fusion of the musculocutaneous nerve with median nerve. In 3 limbs (6%), the communicating branch arose from the musculocutaneous nerve within the coracobrachialis muscle and in 8 limbs (16%) the branch arose from the musculocutaneous nerve distal to the aforesaid muscle. In 74% cases (37 out of 50 specimens) we didn't find any communication. In case of complete fusion, the thickness of the musculocutaneous nerve was more than the lateral root of median nerve in both the 2 limbs. The mean distance between the point of formation of the musculocutaneous nerve and the formation of the communicating branch was 3.38cm and between the point of formation of median nerve and point of joining of communicating branch with it was 8.20cm. We found the mean length of the communicating branch 6.5cm. The mean distance from the tip of the coracoid process to the origin of the communicating branch from musculocutaneous nerve is 8cm and the same upto the joining with the median nerve is 13.6 cm. In case of complete fusion (4%) we found the mean distance from the tip of the coracoid process to the formation of musculocutaneous nerve is 4.7cm and it is 12.2cm upto its fusion with the median nerve i.e formation of common trunk.




Fig. 1 showing CB(communucating branch) arising within CBM(coracobrachialis muscle)
MN: median nerve, MCN: musculocutaneous nerve.




Fig. 2 showing CB(communucating branch) arising distal to CBM(coracobrachialis muscle)
MN: median nerve, MCN: musculocutaneous nerve.

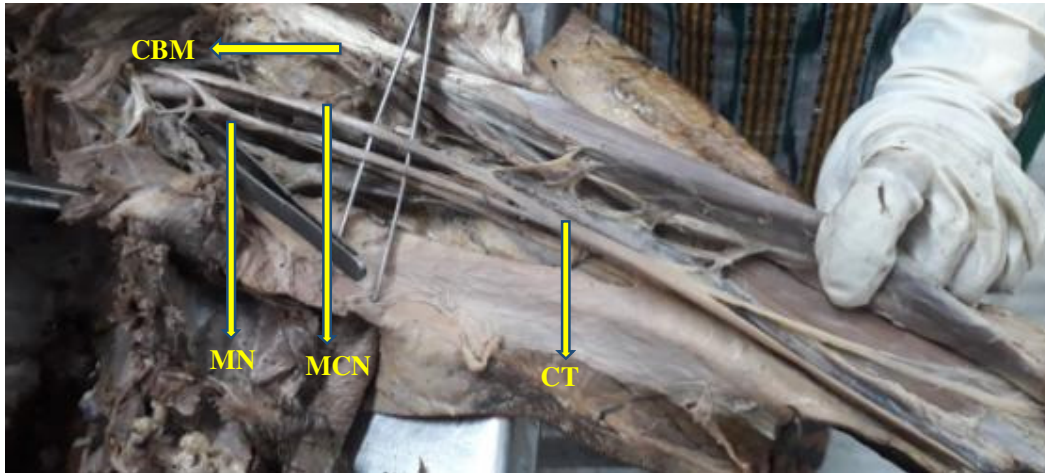

Fig 3 showing complete fusion of MCN (musculocutaneous nerve) with MN (median nerve) thus forming a CT (common trunk), CBM: coracobrachialis muscle.

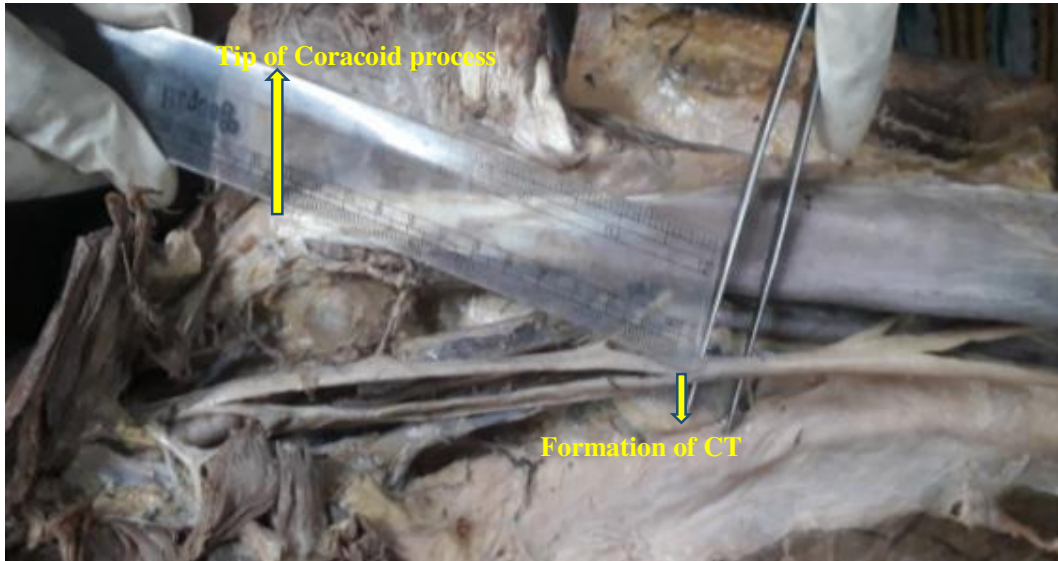


Fig 4 showing distance (12.2 cm) from the tip of coracoid process to the formation of CT (Common trunk).

DISCUSSION

The connection between the musculocutaneous nerve and median nerve has been the topic of discussion for decades all over the world. In 1998, Venieratos and Anagnostopoulou reported in their study on brachial plexus that the communication between the musculocutaneous and median nerve is the most common variation.³

Worldwide different authors have taken different methods for classification of musculocutaneous

nerve as well as the variation of communication between the musculocutaneous and median nerve.^{3,12,13,14,15}

In India also there are different studies and case reports on this variation from different regions of this country.^{9,10,11,16,17,18,19,20,21}

In 2013, Chaudhary et al in their study in north India described this variation under 3 types ; absence of musculocutaneous nerve (10%), communication between musculocutaneous and

median nerve (10%) and complete fusion of the musculocutaneous and median nerve(6.66%).⁹ In our study we did not get any limb where musculocutaneous nerve was absent. This result correlates with that found by Gopal et al in 2016, in north India (0% cases of absence of musculocutaneous nerve).¹⁶

The communication between the two nerves we get is 22% and in 4% cases there were complete fusion. Gopal et al in 2016 found an unusual communication which joined the musculocutaneous nerve to the median nerve before entering the coracobrachialis muscle (2.25%) and in 5 % cases the communicating branch arose from the musculocutaneous nerve after the later coming out of the muscle.¹⁶In our study, we did not found any case where the communicating branch arose from the musculocutaneous nerve before piercing the muscle. In 16% cases we found the communicating branch to arise after the exit of musculocutaneous nerve from the coracobrachialis muscle and in 3 limbs (6%) we noticed the communicating branch to arise within the muscle from the musculocutaneous nerve.

In 2016, in a south India based study, Jagadeesh et al found the presence of the communicating branch in 4% cases only.¹⁹ In another south India based study in 2016, Vanisree et al found 6.66% and 18.3% cases respectively where the communication was proximal to the entry of musculocutaneous nerve into coracobrachialis muscle and distal to the exit of the same nerve from the aforesaid muscle.¹⁰ In a study done by Zarna K Patel et al in 2017 in western India reported 6.66% of cases of communication between the musculocutaneous nerve and the median nerve.¹¹ Table 1 compares the variation of communication.

Chaudhary P et al in their study found some specimen with thicker musculocutaneous nerve than lateral root of median nerve as well as lateral root of median nerve with normal diameter in cases of complete fusion.⁹ But in our study we found all limbs with thicker musculocutaneous nerve than lateral root of median nerve in cases of complete fusion of musculocutaneous nerve with the median nerve.

According to Bergman et al (1988) the communicating branch commonly joins with the median nerve in the lower third of the arm.²²Regarding the exact topography, table 2 compares the mean values of distances among our study with previous studies.

In our study we also noted the distances from the tip of the coracoid process. Being a bony point it is fixed and may have immense value for surgeons during operating procedures and anaesthetists during regional block.

These abnormal communications between the musculocutaneous nerve and the median nerve have been explained by different authors. Embryologically it has been explained by neuronal growth cone which are mediated by intracellular signalling pathways which link guidance receptors regulated by expression of chemo-attractants and chemo-repellents, to the cytoskeleton.²³Alterations in signalling between growth cone and mesenchymal cells may lead to these variations.¹¹ In amphibians, reptiles and birds there was only one trunk in the thoracic limb.²⁰ It may be that the cords of the brachial plexus in higher vertebrates arises from one mother trunk and thus explains the abnormal communications between the musculocutaneous and median nerve.²⁴

Table 1: Comparison between previous studies

Name of the Authors	CB proximal to the CBM	CB within the CBM	CB distal to the CBM	Total CB	Absence of MCN	Complete fusion
Watanabe et al (1985) ²⁸	----	----	----	1.4%	----	1.4%
Yang et al (1995) ¹³	----	----	----	12.5%	----	4%
Chaudhary et al (2013) ⁹	----	----	----	10%	10%	6.66%
Gopal et al (2016) ¹⁶	2.25%	----	5%	----	----	----
Jamuna et al (2011) ²⁵	----	----	----	----	6%	2%
Vanisree et al (2016) ¹⁰	6.66%	----	18.3%	----	----	----
Zarna et al (2017) ¹¹	----	----	----	6.66%	----	----
Present study (2018)	0%	6%	16%	22%	0%	4%

CB: communicating branch, CBM: coracobrachialis muscle, MCN: musculocutaneous nerve,

Table 2: Comparison of different distances with previous studies.

Name of the Authors	Total no of limbs studied	% of limbs having CB	Dis b/w formation of MCN & of CB(mean)	Dis b/w formation of MN & joining of CB(mean)	Length of CB(mean)
Rao and Chaudhury (2000) ⁵	24	33.33%	15.5	NR	8.95
Aktan et al (2000) ²⁷	48	10.40%	0.95 ± 0.42	10.25 ± 2.32	5.50
Chaudhury et al (2013) ⁹	60	10.00%	2.98	5.21	4.3
Present study	50	22.00%	3.38	8.20	6.5

NB: all mean values are in cm.

CONCLUSION

The anomalous communication between the musculocutaneous nerve and the median nerve is of great importance for anatomists, surgeons as well as anaesthetists.⁵

During shoulder surgeries, coracoid process grafting, dislocation of shoulder and arthroscopies, it is important to identify the musculocutaneous nerve, as it is prone to get injured during placement of retractors under the coracoid process^{1, 25,26} Any injury to the musculocutaneous nerve proximal to the communication may cause unexplained

weakness of flexors of forearm and thenar muscles.

If there is any entrapment of musculocutaneous nerve or the communicating branch within the coracobrachialis muscle, it may exhibit signs and symptoms of median nerve neuropathy, as some fibres of median nerve go through the musculocutaneous nerve¹⁰so knowledge about exact topography, types and incidence of these variations of communication between musculocutaneous and median nerve can be very useful.

REFERENCES

1. Gatzoulis MA. Thorax. In ;Gray's Anatomy. 40th ed. Edinburg, Churchill Livingstone; 2008: p.831-832
2. Necdet K, Bulent Y, Cent K, Hasan O. Multiple anomalies of brachial plexus: a case report. Neuroanatomy 2007; 6: 21-3
3. Venieratos D, Anagnostopoulou S. Classification of communications between the musculocutaneous and median nerves. Clin Anat 1998;11(5): 327-31
4. Le Minor JM. A rare variation of the median and musculocutaneous nerves in man. Arch Anat Histol Embryol 1990;73:33-42
5. Prasada Rao PV, Chaudhary SC. Communication of the musculocutaneous nerve with the median nerve. East Afr Med J 2000;77(9):498-503

6. Sud M, Sharma A. Absence of musculocutaneous nerve and the innervation of coracobrachialis, biceps brachii and brachialis from the median nerve. *J Anat Soc India* 2000;49(2):176-7
7. Rajashree B, Arati D, Mamata S, Chinmayi M, Charulata S. Absence of musculocutaneous nerve – a case report. *J Anat Soc India* 2003;52(1):94
8. Saritha S. Variations in the median and musculocutaneous nerves – A surgical prospective. *J Anat Soc Ind* 2004;53(1):31-66
9. Chaudhary P, Kalsey G, Singla R, Arora K. Communication between musculocutaneous and median nerve – Different types and their incidence in north Indian population. *Indian Journal of Clinical Practice* 2013;24(3):364-71
10. Vanisree S. K., Jayamma Ch., Kumari V. S., Sugavasi R. Study of variations of musculocutaneous nerve in relation to the coracobrachialis muscle. *International journal of contemporary medical research* 2016;3(10):2863-65
11. Patel Z K, Gupta S, Chaudhary S. Cadaveric study of abnormal communication between cords and branches of brachial plexus. *Int J Anat Res* 2017;5(2.1):3741-45
12. Kosugi K, Shibata S, Yamashita H. Supernumerary head of biceps brachii and branching pattern of the musculocutaneous nerve in Japanese. *Surg Radiol Anat* 1992;14: 175-85
13. Yang ZX, Pho RW, Kour AK, Pereira BP. The musculocutaneous nerve and its branches to the biceps and brachialis muscle. *J Hand Surg Am* 1995;20: 671-75
14. Choi D, Rodriguez-Niedenfuhr M, Vazquez T, Parkin I, Sanudo JR. Patterns of connections between the musculocutaneous and median nerves in the axilla and arm. *Clin Anat* 2002;15:11-17
15. Buch-Hansen K. Variations of the median nerve and the musculocutaneous nerve and their connections. *Anat Anz* 1955;102:187-203
16. Gopal K, Anurag, Singh O. Anatomical variations of brachial plexus: anomalous branching pattern. *Int J Res in Med Sciences* 2016;4(8):3376-80
17. Chauhan R, Roy TS. Communication between the median and musculocutaneous nerve – a case report. *J Anat Soc India* 2002;51(1):72-75
18. Ghosh I, Sengupta G, Basu P, De(Bose) A. Anomalous branches of median nerve in the arm. *Int J Anat Res* 2014;2(4):653-56
19. Babu DJ, Pillai TJ, Priyanka KD, Jalaja Y, Kumar US. A study on variations of musculocutaneous nerve in adult cadavers. *IOSR J Dental and Med Sci* 2016;15(5):14-17
20. Saha D, Bhattacharya S. Variations in formation of median and musculocutaneous nerves and their unusual branches – a case study. *Indian J of Basic and applied Med Res* 2016;5(4):111-15
21. Saha DK, Majumdar S, Pradhan S, Sarkar A, Bapuli C. Variations in the musculocutaneous and median nerves in a single cadaver. *Int J Anat* 2014;3(4):4-6
22. Bergman RA, Thompson SA, Afifi AK, Saadeh FA. *Compendium of human anatomic variation*. Urban & Schwarzeberg Munich. 1988;139-43
23. Gabriel J Mchonde. Bilateral multiple variations in the formation of brachial plexus. *Int J Anat Res* 2013;1(2):78-82

24. Ray A, Bhattacharya S, Dutta S, Mandal L, Majumdar S. An evaluation of the system of classifications of the median and musculocutaneous nerves: A study in West Bengal population. Indian Journal of Basic and Applied Medical Research. 2013;8(2):841-53
25. M Jamuna, G Amudha. A cadaveric study on the anatomic variations of the musculocutaneous nerve in the infraclavicular part of the brachial plexus. J Clin Diagn Res(JCDR) 2011; 5(6):1144-47
26. Williams PL, Bannister LH, Berry MM. Gray's Anatomy in Embryology and development. 38th edition London ChurchillLivingstone, 1999: 231-32
27. Atkan ZA, Ozturk L, Bilge O, Ozer MA, Pinar YA. A cadaveric study of the anatomic variations of the brachial plexus nerves in the axillary region and arm. Turk J Med Sci 2000;31:147-50
28. Watanabe M, Takatsuji K, Sakamoto N, Morit Y, Ito H. Two cases of fusion of the musculocutaneous and median nerves. Kalbo gaki Zasshi 1985; 60: 1-7